



A case of pulmonary cryptococcoma due to *Cryptococcus gattii* in the United Kingdom

DOI:
[10.1016/j.mmcr.2018.03.007](https://doi.org/10.1016/j.mmcr.2018.03.007)

Document Version
Final published version

[Link to publication record in Manchester Research Explorer](#)

Citation for published version (APA):

Rodriguez-Goncer, I., Bongomin, F., Doran, H., Novak Frazer, L., Masania, R., Moore, C., & Richardson, M. (2018). A case of pulmonary cryptococcoma due to *Cryptococcus gattii* in the United Kingdom. *Medical Mycology Case Reports*, 21, 23-25. <https://doi.org/10.1016/j.mmcr.2018.03.007>

Published in:
Medical Mycology Case Reports

Citing this paper

Please note that where the full-text provided on Manchester Research Explorer is the Author Accepted Manuscript or Proof version this may differ from the final Published version. If citing, it is advised that you check and use the publisher's definitive version.


General rights

Copyright and moral rights for the publications made accessible in the Research Explorer are retained by the authors and/or other copyright owners and it is a condition of accessing publications that users recognise and abide by the legal requirements associated with these rights.

Takedown policy

If you believe that this document breaches copyright please refer to the University of Manchester's Takedown Procedures [<http://man.ac.uk/04Y6Bo>] or contact uml.scholarlycommunications@manchester.ac.uk providing relevant details, so we can investigate your claim.





A case of pulmonary cryptococcoma due to *Cryptococcus gattii* in the United Kingdom

Isabel Rodriguez-Goncer^{a,*,1}, Felix Bongomin^{b,c,1}, Helen M. Doran^d, Lily Novak-Frazer^{b,e}, Rikesh Masania^{b,e}, Caroline B. Moore^{b,e}, Malcolm D. Richardson^{b,e}

^a Department of Infectious Diseases, Wythenshawe Hospital, Manchester University NHS Foundation Trust, Manchester M23 9LT, UK

^b Division of Infection, Immunity and Respiratory Medicine, Faculty of Biology, Medicine and Health, University of Manchester, Manchester M13 9PL, UK

^c Global Action Fund for Fungal Infections, Rue de l'Ancien-Port 14, 1211 Geneva 1, Switzerland

^d Department of Pathology, Wythenshawe Hospital, Manchester University NHS Foundation Trust, Manchester M23 9LT, UK

^e Mycology Reference Centre, ECMM Excellence Centre of Medical Mycology, Manchester University NHS Foundation Trust, Manchester M23 9LT, UK

ARTICLE INFO

Keywords:

Cryptococcus gattii
Biological therapy
United Kingdom

ABSTRACT

We report a case of *Cryptococcus gattii* infection in the UK in a 76-year-old woman on biologic therapy for intra-abdominal non-Hodgkin lymphoma. An incidental nodular lung lesion was found on a chest imaging and histology, culture and molecular mycology studies of the lobectomy specimen revealed the presence of *C. gattii*.

1. Introduction

Cryptococcus neoformans and *Cryptococcus gattii* are the two etiologic agents of nearly all human and animal cryptococcosis. Advanced acquired immunodeficiency syndrome is the most common risk factor for cryptococcosis caused by *C. neoformans* worldwide. *C. gattii* is responsible for < 20% of the global cases of human cryptococcosis, often reported in immunocompetent patients in endemic tropical and subtropical climatic regions, including Papua New Guinea, Australia, and many countries of South America where the fungus is known to grow on some specific tree species [1].

The first reported case of *C. gattii* infection was described in Africa in 1966, several cases have been reported in some countries in Asia and sporadic reports of *C. gattii* infection have occurred in Europe and Mexico [2]. In the last 15 years, the number of case reports of *C. gattii* infection outside of the traditionally endemic regions has increased, including outbreaks in Vancouver Island, British Columbia, Canada and from the Pacific Northwest of the United States (US). The source is usually traced back to trees [3,4]. The first observation of an imported *C. gattii* infection in the UK was in 2004 in an HIV-infected man who had recently returned from a 4-year stay in South Africa [5]. Evidence of environmental isolation of *C. gattii* across six continents has been published but not in the UK [6]. Herein, we report an incidental and very rare finding of pulmonary cryptococcosis due to *C. gattii* in a 76-year-old Caucasian female on biological therapy in the UK.

2. Case

In April 2017, we received a 76-year-old Caucasian female at Wythenshawe Hospital, Manchester (UK) having been referred by her physician following an incidental radiological finding of a small lung nodule in the right upper lobe. Her past medical history is significant for an intra-abdominal non-Hodgkin lymphoma (NHL) diagnosed in 2009 for which she is currently receiving ibrutinib after 2 relapses in 2010 and 2014 while on chemotherapy. Radiologically on a chest X-Ray (day 0), the lesion was highly suspicious for primary lung cancer. The patient was clinically asymptomatic with no respiratory, neurologic or systemic symptoms. At day + 5, she subsequently underwent a computerised tomography (CT) (Fig. 1A) and positron emission tomography (PET) scans which showed high metabolic activity of the nodule. There were no other signs of recurrence of her lymphoma. The patient had never smoked herself but her husband was a heavy smoker who later died from lung cancer. Percutaneous needle biopsy of the nodule done at day + 7 was unyielding. At day + 30, the mass was subsequently resected completely by a right upper lobectomy and samples were sent for histology and microbiological studies. Histology demonstrated a cystic mass with caseating necrosis and surrounding granulomatous reactions including multinucleate giant cells with no evidence of malignancy. Round to oval bodies were seen within the necrotic materials, having a faintly birefringent wall and a "halo", varying in size and up to 25 mm in diameter (Fig. 1B). The appearance was suggestive of

* Corresponding author.

E-mail address: isargoncer@gmail.com (I. Rodriguez-Goncer).

¹ The first two authors contributed equally to this article.

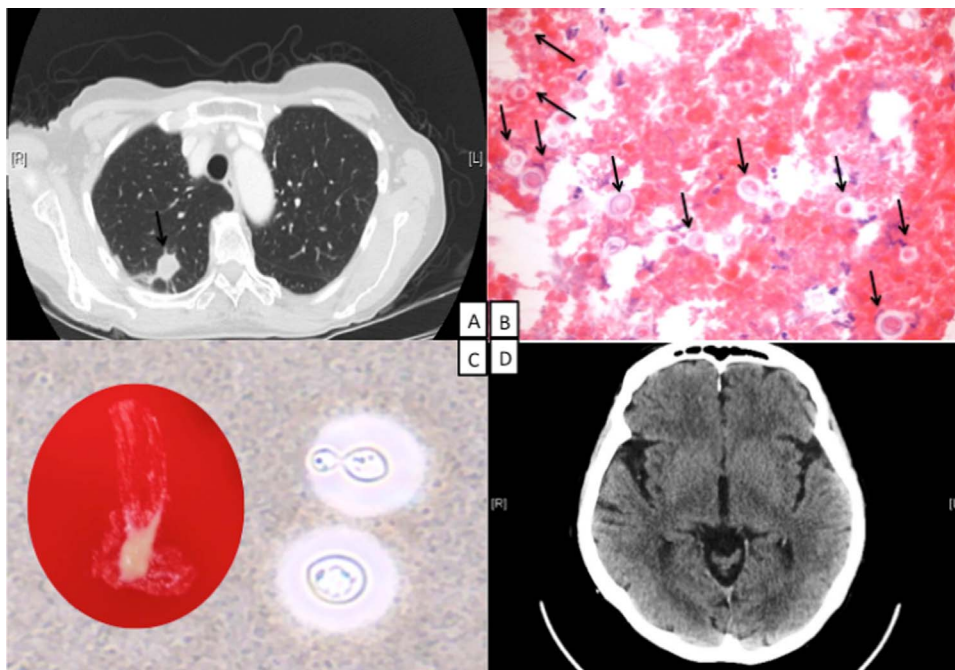


Fig. 1. A. Right upper lobe nodule. B. Numerous encapsulated, budding yeasts on a paraffin frozen section of the lung nodule. C. India ink preparation showing encapsulated, budding yeasts containing volutin granules following 48 h growth on blood agar (insert). D. Normal brain on a non-contrasted axial head CT scan with no evidence of a space occupying lesion or midline shift.

Cryptococcus spp. Grocott's methenamine silver stain was positive and Ziehl-Neelsen stain was negative. Mycological culture identified *Cryptococcus* species (Fig. 1C). Molecular sequencing of the internal transcribed spacer and 26sRNA regions of genomic extracts of cultured isolate determined the identification as *C. gattii*.

In her travel history, she visited the Caribbean and US (New York) in the late 1980s. Over 10 years ago, she travelled to Cyprus (several times) and France (Paris). She also went to Spain (Barcelona) 3 years ago but had not travelled outside of the UK since then.

We reviewed the patient at the Infectious Diseases clinic at day + 60. She remained asymptomatic and her inflammatory markers were within the normal limits. Her serum cryptococcal antigen (CrAg) and HIV test were negative. In the same visit, a brain CT scan showed no abnormalities (Fig. 1D). We therefore considered the infection to be localised and fully excised and a clinical decision not to give any antifungal therapy was reached. At day + 210, she remained well with no symptoms and was discharged from the infectious diseases clinic.

3. Discussion

Human cryptococcosis is acquired through inhalation of desiccated blastoconidia of *Cryptococcus* spp into the respiratory tract [1]. *C. gattii* usually infects the lungs or the central nervous system but it can also affect other parts of the body. This species of *Cryptococcus* has the tendency to cause mass lesions (cryptococcomas) in the lungs, skin, brain or other organs and has a higher propensity to cause meningoencephalitis with cerebral cryptococcoma than *C. neoformans*. As seen in our patient, pulmonary cryptococcosis takes an indolent course; patients are usually asymptomatic or frequently present with subtle clinical manifestations such as a subacute or chronic cough with negative respiratory cultures for the pathogen [7]. CrAg is less sensitive in HIV-uninfected individuals, often negative in localised pulmonary infection and cannot differentiate *C. gattii* from *C. neoformans*.

The pathogenesis of pulmonary cryptococcosis is poorly understood and the differential diagnoses are broad, including primary and metastatic lung cancers and other pulmonary fungal infections [7]. The incubation period of *C. gattii* is not well established and the major risk factors for the development of the disease are unclear. The average incubation period associated with the outbreaks appeared to be between 2 and 13 months but can be up to 3 years after infection [8,9].

Although most reported cases of *C. gattii* infection appear to be primary infections, infrequent reports of reactivations of latent *C. gattii* infections in immunocompetent patients have described symptoms occurring over 20 years after likely exposure, which suggests that *C. gattii* may have a greater capacity to remain dormant [10]. Thus, our patient could potentially have been exposed while in the Caribbean and have experienced a reactivation of latent infection in the setting of immunosuppressive therapy. However, an extensive environmental survey done recently in the Mediterranean basin yielded *C. gattii* in Greece, Southern Italy and Spain but not in Cyprus [11]. She could also potentially have been exposed to the fungus during her trip to Northern Europe. Alternatively, the patient may have been exposed to an unknown environmental source in the UK.

Oral fluconazole is the treatment of choice for symptomatic patients with single small cryptococcoma and amphotericin B for those with very large and multiple cryptococcomas. Surgery is only considered in cases of compression of vital structures, failure to thrive, or failure to reduce size of cryptococcoma after 4 weeks of antifungal therapy [12]. However, in our patient, surgery was both diagnostic and therapeutic without any additional requirements for antifungal therapy.

In conclusion, with outbreaks of *C. gattii* infections on Vancouver Island in Canada and the Pacific Northwestern United States, it is clear that this organism has expanded its niche beyond the tropical and subtropical climatic regions to the temperate zones. Infection due to *C. gattii* should thus be suspected in a patient outside of the endemic region with relevant travel history or compatible clinical manifestations.

Acknowledgements

None.

Conflict of interest

There are none.

References

- [1] K.J. Kwon-Chung, J.A. Fraser, T.L. Doering, Z. Wang, G. Janbon, A. Idnurm, Y.S. Bahn, *Cryptococcus neoformans* and *Cryptococcus gattii*, the etiologic agents of cryptococcosis, Cold Spring Harb. Perspect. Med. 4 (2014) a019760, <http://dx.doi.org/10.1101/cshperspect.a019760>.

- [2] J. Harris, S. Lockhart, T. Chiller, *Cryptococcus gattii*: where do we go from here? *Med. Mycol.* 50 (2012) 113–129, <http://dx.doi.org/10.3109/13693786.2011.607854>.
- [3] E. Galanis, L. MacDougall, Epidemiology of *Cryptococcus gattii*, British Columbia, Canada, 1999–2007, *Emerg. Infect. Dis.* 16 (2010) 251–257, <http://dx.doi.org/10.3201/eid1601.090900>.
- [4] S.R. Lockhart, O.Z. McCotter, T.M. Chiller, Emerging fungal infections in the Pacific Northwest: the unrecognized burden and geographic range of *Cryptococcus gattii* and *Coccidioides immitis*, *Microbiol. Spectr.* 4 (2016) 375–384, <http://dx.doi.org/10.1128/microbiolspec.EI10-0016-2016>.
- [5] N. Bodasing, R.A. Seaton, G.S. Shankland, D. Kennedy, *Cryptococcus neoformans* var. *gattii* meningitis in an HIV-positive patient: first observation in the United Kingdom, *J. Infect.* 49 (2004) 253–255, <http://dx.doi.org/10.1016/j.jinf.2003.06.001>.
- [6] E.S. Acheson, E. Galanis, K. Bartlett, S. Mak, B. Klinkenberg, Searching for clues for eighteen years: deciphering the ecological determinants of *Cryptococcus gattii* on Vancouver Island, British Columbia, *Med. Mycol.* (2017) 1–16, <http://dx.doi.org/10.1093/mmy/myx037>.
- [7] C.C. Chang, T.C. Sorrell, S.C.-A. Chen, Pulmonary Cryptococcosis, *Semin. Respir. Crit. Care Med.* 36 (2015) 681–691, <http://dx.doi.org/10.1055/s-0035-1562895>.
- [8] L. MacDougall, M. Fyfe, Emergence of *Cryptococcus gattii* in a novel environment provides clues to its incubation period, *J. Clin. Microbiol.* 44 (2006) 1851–1852, <http://dx.doi.org/10.1128/JCM.44.5.1851-1852.2006>.
- [9] K.A. Johansson, S.M. Huston, C.H. Mody, W. Davidson, *Cryptococcus gattii* pneumonia, *CMAJ* 184 (2012) 1387–1390, <http://dx.doi.org/10.1503/cmaj.111346>.
- [10] F. Dromer, O. Ronin, B. Dupont, Isolation of *Cryptococcus neoformans* var. *gattii* from an Asian patient in France: evidence for dormant infection in healthy subjects, *Med. Mycol.* 30 (1992) 395–397, <http://dx.doi.org/10.1080/02681219280000511>.
- [11] M. Cogliati, R. D'Amicis, A. Zani, M.T. Montagna, G. Caggiano, O. De Giglio, S. Balbino, A. De Donno, F. Serio, S. Susever, C. Ergin, A. Velegraki, M.S. Ellabib, S. Nardoni, C. Macci, S. Oliveri, L. Trovato, L. Dipineto, V. Rickerts, I. McCormick-Smith, S. Akcaglar, O. Tore, E. Mlinaric-Missoni, S. Bertout, M. Mallié, M. da, L. Martins, A.C.F. Vencà, M.L. Vieira, A.C. Sampaio, C. Pereira, G. Griseo, O. Romeo, S. Ranque, M.H.Y. Al-Yasiri, M. Kaya, N. Cerikcioglu, A. Marchese, L. Vezzulli, M. Ilkit, M. Desnos-Ollivier, V. Pasquale, M. Korem, I. Polacheck, A. Scopa, W. Meyer, K. Ferreira-Paim, F. Hagen, B. Theelen, T. Boekhout, S.R. Lockhart, K. Tintelnot, A.M. Tortorano, F. Dromer, A. Varma, K.J. Kwon-Chung, J. Inácio, B. Alonso, M.F. Colom, Environmental distribution of *Cryptococcus neoformans* and *C. gattii* around the Mediterranean basin, *FEMS Yeast Res.* 16 (2016) fow045, <http://dx.doi.org/10.1093/femsyr/fow045>.
- [12] J.R. Perfect, W.E. Dismukes, F. Dromer, D.L. Goldman, J.R. Graybill, R.J. Hamill, T.S. Harrison, R. a. Larsen, O. Lortholary, M.-H. Nguyen, P.G. Pappas, W.G. Powderly, N. Singh, J.D. Sobel, T.C. Sorrell, Clinical practice guidelines for the management of cryptococcal disease: 2010 update by the infectious diseases society of america, *Clin. Infect. Dis.* 50 (2010) 291–322, <http://dx.doi.org/10.1086/649858>.